Frontiers in Health Informatics
ISSN-Online: 2676-7104
www.healthinformaticsjournal.com
2025; Vol 14: Issue 2
Open Access

Histopathological and Bacteriological Evaluation of the Maxillary Sinus after Sinus Lifting Procedure: An Experimental Study in a Rabbit Model

Mahmoud Hassan Eid[1], Diaa El Din Mohamed El Hennawi[2], Ashraf Saad Abu Halawa[3], Abdelrahman Salah El Demerdash[4], Asmaa K. K. Abdelmaogood[5], Wael Abdo Hassan[6], Mahmoud Mohamed Soliman[7]

1. Assistant lecturer of Otolaryngology, Faculty of medicine, Suez Canal University, Ismailia, Egypt; mahmoudhassan@med.suez.edu.eg; ORCID-ID: 0000-0001-5850-2626
2. Professor of Otolaryngology, Faculty of medicine, Suez Canal University, Ismailia, Egypt; dhennawi@yahoo.com; ORCID-ID: 0000-0001-6120-8196
3. Professor of Otolaryngology, Faculty of medicine, Suez Canal University, Ismailia, Egypt; ashraf_abouhalawa@med.suez.edu.eg; ORCID-ID: 0000-0002-3442-2135
4. Lecturer of Otorhinolaryngology, Faculty of Medicine, Suez Canal University, Ismailia, Egypt; abdelrahman.salah@med.suez.edu.eg
5. Lecturer of Clinical and Chemical Pathology, Faculty of Medicine, Suez Canal University, Ismailia, Egypt; asmaa.kamal@med.suez.edu.eg; ORCID ID: 0000-0002-6304-2537
6. Lecturer of Pathology, Faculty of Medicine, Suez Canal University, Ismailia, Egypt; Wael.hassan@sharjah.ac.ae ORCID ID: 0000-0003-0613-9161
7. Lecturer of Otolaryngology, Faculty of medicine, Suez Canal University, Ismailia, Egypt; mahmoud.elyamany@med.suez.edu.eg; ORCID ID: 0000-0001-8956-7916

Cite this paper as: Eid M.H, El Hennawi D.E.M, Abu Halawa A.S, El Demerdash A.S, Abdelmaogood A.K.K, Hassan W.A, Soliman M.M (2025) Histopathological and Bacteriological Evaluation of the Maxillary Sinus after Sinus Lifting Procedure: An Experimental Study in a Rabbit Model *Frontiers in Health Informatics*, *Vol.14, No.2*, 2483-2498

ABSTRACT

BACKGROUND: Rabbits have been used for establishing a new animal experimental model. The rabbit experimental model of maxillary sinus augmentation was firstly introduced by Watanabe et al. They stated that the advantages of the rabbit model were low cost, ease of experimentation, and easy distinction of membrane perforation. After their introduction of this model, successful experiments using the rabbit sinus model were performed by others. However, the previous studies had mainly focused on the response of various graft materials in the sinus without implant placement.

AIM: This study aimed to assess the histopathological and bacteriological outcomes of sinus lifting procedure on the maxillary sinus in a rabbit model.

MATERIALS & METHODS: This experimental animal study was conducted on 42 rabbits. The rabbits are divided into three groups: Group I (n=14): the operation was conducted in rabbits with intact sinus mucosa where the bone graft was placed under an intact sinus mucosal membrane, group II (n=14): the operation was conducted in rabbits with intentionally perforated sinus mucosa. Where the bone graft material was placed under the sinus membrane and inside the sinus cavity after a swab was taken for bacteriological culture and group III (n=14): the same procedure was done as in group two, but after two weeks, removal of the graft material with another swab was taken for bacteriological culture to detect changes in the sinus bacterial flora.

RESULTS: In the current study at baseline evaluation 25% had Pasteurella multocida, 14.3% had staphylococcus aureus and 3.6% had streptococcus pneumonia. There was statistical insignificant difference in bacterial growth among the studied groups (p=0.707). As group II had higher growth (50%) than group III (35.7%) with insignificant difference. In group II, 28.6% had Pasteurella multocida, 14.3% had staphylococcus aureus and 7.1% had streptococcus pneumonia. Among group III, 21.4% had Pasteurella multocida and 14.3% had staphylococcus aureus. After two weeks, among group III, there was significant increase in bacterial growth from (35.7%) to (64.3%) with statistically significant difference (p=0.004). After 2 weeks, microbiological evaluation detected 2 cases with Streptococcus Pneumonia, one case with Escherichia coli and one case with pseudomonas aeruginosa. In the present study, regarding thinning and perforation of the Schneiderian membrane, we found that there were no thinning nor perforation of the Schneiderian membrane among group I, while 85% of group II and 20% in group III showed thinning and perforation of the Schneiderian membrane with statistically significant difference (p<0.001). Group I had intact mucosa, 90% new bone mineralization and 10% inflammatory infiltrate. In group II, mucosa showed Perforation with attempts for healing, absence of new bone mineralization and 75% showed inflammatory infiltrate. In group III, there was focal ulceration of mucosa, 35% new bone mineralization and 45% inflammatory infiltrate.

CONCLUSION: If the maxillary sinus lifting is performed on top of an undamaged Schneiderian membrane, it is a rather safe and effective treatment. Although a little inflammatory response is anticipated, our data clearly shows new bone growth. The graft material is exposed by Schneiderian membrane penetration within the sinus cavity, which may impede the deposition of new bone for the intended implant installation and cause inflammatory cell aggregation. In order to improve patient outcomes by increasing the predictability and safety of maxillary sinus

lifting operations, this research also emphasizes the need of multidisciplinary cooperation between the otolaryngologist and oral surgeon..

Keywords: Maxillary Sinus, Sinus Lifting Procedure, Rabbit Model.

INTRODUCTION

Pneumatization of the sinus cavity toward the alveolar crest and the physiological bone remodeling process that follows tooth loss in the posterior maxilla both increase the likelihood of alveolar bone resorption. A regenerative surgical treatment known as the maxillary sinus lifting operation is necessary because these processes lead to reduced bone availability for the insertion of dental implants [(1)].

The intact sinus membrane and surrounding bone protect the apical end of implants that protrude through the sinus cavity when there is sufficient basal alveolar bone for secure implant placement. A bone replacement graft is often used to fill the residual space in the sinus cavity around the implant when there is not enough basal bone to serve as the implant's primary support. In maxillary sinus lifting treatments, a variety of biomaterials have been employed as bone replacement grafts. These include autologous bone, synthetic biomaterials, bone replacements, and combinations of these [(2)].

In addition to jeopardizing the feasibility of the bone augmentation treatment, sinus membrane perforations during surgery lengthen operating times and raise the risk of problems after surgery. Additionally, a decreased implant survival rate has been linked to these perforations. Both the transcrestal and lateral window techniques have also been documented to extrude biomaterial into the sinus cavity. It might occur during the procedure or subsequently, in which case the implants could puncture the sinus mucosa after sinus floor elevation. According to Hernandez-Alfaro et al. [(3)] the incidence of chronic rhinosinusitis when the graft is extruded into the sinus canal during sinus lifting is minimal, ranging from 4.2% to 8.4%.

Although sinus lifting is becoming more and more common as a way to provide enough bone height for a safe and effective implant placement, it has not been extensively studied in relation to the maxillary sinus. [(4)] No prior research, as far as we are aware, has assessed the histopathological and bacteriological impact of the sinus lifting procedure on the maxillary sinus mucosa, either intact or perforated, with the graft exposed inside the sinus and following surgical removal of the graft material displaced inside the sinus cavity in cases where the sinus mucosal membrane is perforated.

Aim

The aim of this study was to assess the histopathological and bacteriological outcomes of sinus lifting procedure on the maxillary sinus in a rabbit model.

Methods and Materials

Research design

The animal house of the Faculty of Medicine, Suez Canal University served as the housing for the experimental animal research, and the animal model underwent surgical procedures there. The Faculty of Medicine at Suez Canal University's Research and Ethics committee gave its approval to all experimental operations. On September 11, 2022, Protocol No. 5044 was issued. The animal model underwent the surgical process of sinus lifting and graft insertion at Suez Canal University's Faculty of Medicine's animal house.

Egyptian Baladi White male rabbits, ranging in age from 5 to 6 months, weighing between 2 and 2.5 kg on average and showing no symptoms of upper respiratory tract infections are the animal model of choice for our work.

Each rabbit had unilateral surgery to open one sinus, with the opposite side serving as a control. Under the proper anesthesia, the sinus's bony wall was exposed. The lateral wall was then removed, elevating the sinus mucous membrane and placing the bone graft material. This procedure is somewhat similar to the lateral window technique used in human sinus augmentation. The 42 rabbits were divided into three groups.

Group I: the operation was conducted on top of an intact sinus mucosa where the bone graft was placed under an intact sinus mucous membrane.

Group II: the operation was conducted on top of an intentionally perforated sinus mucosa and the bone graft material was placed under the sinus membrane and inside the sinus cavity after a swab was taken for bacteriological culture to detect baseline bacterial flora.

Group III: the same procedure was done as in group two, but after two weeks, removal of the graft material with another swab was taken for bacteriological culture to detect changes in the sinus bacterial flora.

At the fourth week, histopathological evaluation of the maxillary sinus mucosa and the underlying tissues in each rabbit was done to detect changes that occur after sinus lifting in cases with:
Successful surgical procedure on top of intact sinus mucosa.
Perforated sinus mucosa with the graft displaced inside the sinus cavity.
Removal of the graft which was displaced inside the sinus cavity.

Data collection tools

Xenogenic bone graft material (EQUINO-Oss), is a cortico cancellous bone particulates with granules size of (0.25 – 1) mm, made in Germany.

Figure 1: Showing the type of xenogenic graft used in our study.

Light microscope to evaluate the histopathological changes in the sinus mucosa and the underlying tissues.
Bacteriological swab to take samples from the sinus cavity for bacteriological analysis.

Procedures

Baseline assessment

In order to calculate the necessary dosages of anesthetic medications, antibiotics, and the anticipated quantity of bone graft to be inserted in order to prevent sinus overfilling, the animals' weight was assessed before to the experiment. The purpose of a nasal examination is to rule out upper respiratory tract infection symptoms, such as discharge from the nose, sneezing or sniffles, rapid or difficult breathing, wheezing or loud breathing, and discolored hair on the front legs from wiping teary eyes and a runny nose.

Surgical procedure

Housing and husbandry

Each animal received a regular laboratory meal and was kept in a separate cage in a room with regulated light and temperature. Prior to surgery, the animals were fasted for eight hours. For the duration of the trial, a specialized operator kept an eye on biological processes, managed the wounds, and administered the required medications after surgery.

Figure 2 : Showing the rabbit maintained in a separated cage, having free access to water and food.

Anesthesia

The animals were weighed and sedated by an intramuscular (IM) injection of ketamine hydrochloride 1% (10 mg/kg) and xylazine hydrochloride 2% (5 mg/kg) [5].

Figure 3: Showing an intramuscular (IM) injection of ketamine hydrochloride 1% (10mg/kg) and xylazine hydrochloride 2% (5 mg/kg)

Surgical Steps

Following anesthetic induction, the hair covering the work region above the maxilla was appropriately shaved, and 1% aqueous polyvinylpyrrolidone solution was used for antisepsis. For hemostatic and analgesic effects in the initial postoperative phase, local subcutaneous dose of the anesthetic mepivacaine 2% (0.3 mL/kg) and the vasoconstrictor epinephrine 1:100,000 [5].

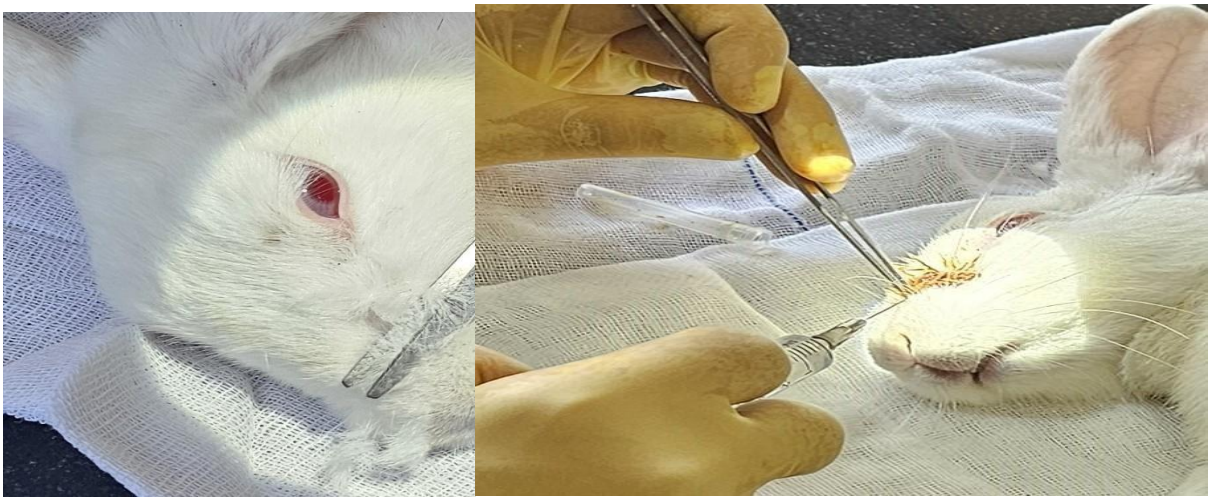

Figure 4: Showing shaving the hair and injection of the local vasoconstrictor and anesthetic agents.

With the aid of a 24 C blade mounted on a scalpel handle, a 3 cm linear incision was made in lateral wall of the maxilla along a line joining the eye and the nostril. The skin and subcutaneous muscles were carefully detached and properly pulled apart with a Molt-type detacher to expose the nasal bone and lateral sinus wall bone. After exposure, the periosteum is carefully elevated to preserve it for later closure at the end of the operation, the bone overlying the maxillary sinus was delicately removed with the aid of a fine bone curette and round knives, preserving the sinus mucosa intact. Special care is taken to avoid injury of the lateral nasal vessel and the nasolacrimal duct.

Figure 5: Showing the lateral nasal vessel overlying the lateral nasal bone.

The graft material placement:

Group I: the graft was placed underneath an intact sinus mucosa.

Group II: intentional perforation of the sinus membrane was done and the graft material was inserted under the sinus membrane and inside the sinus cavity after a swab being taken for bacteriological culture.

Group III: the same procedure was done as in group two, but after a period of 2 weeks, removal of the graft material was done, with another swab taken from the sinus cavity to detect changes in the sinus flora after sinus lifting procedure.

In group I, after elevation of the sinus mucosal membrane, a small amount of the graft material was placed underneath the sinus membrane over the palatal bone, ensuring intact sinus mucosal wall through observing the movement of the sinus mucosa along with respiration, then repositioning of the periosteal flap, suturing the periosteum with sterile synthetic absorbable suture material along with a second layer of closure of the subcutaneous muscles, finally the overlying skin being sutured with sterile monofilament nonabsorbable polypropylene suture material.

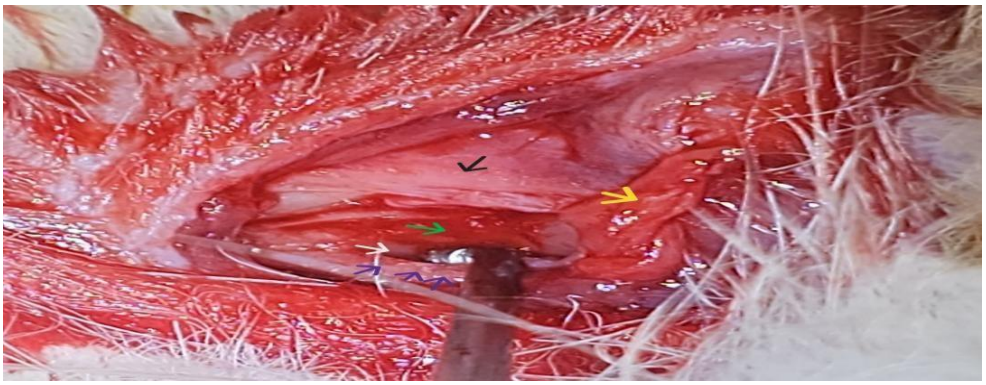

Figure 6: Showing in the first group intact sinus mucosa (green arrow), nasal bone (black arrow), periosteal flap (yellow arrow), palatine bone (purple arrow) and the established space underneath the sinus mucosa (white arrow).

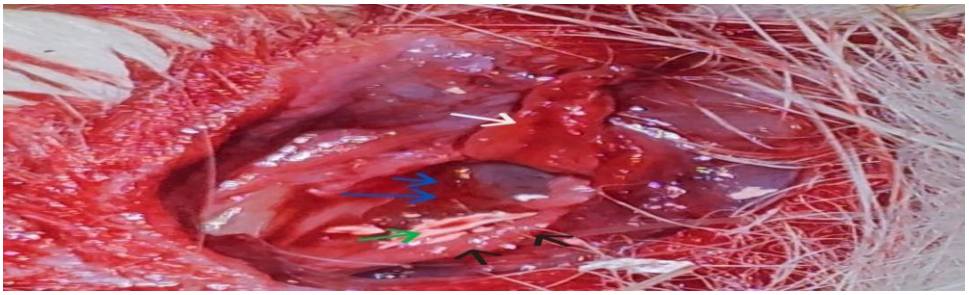

Figure 7**: Showing the graft under intact sinus mucosa (green arrow), palatal bone (black arrow), periosteal flap (white arrow) and intact sinus mucosa (blue arrow).**

Figure 8: Showing closure in layers of the subcutaneous muscles and the skin.

In group II, after exploration of the sinus mucosal membrane, an intentional perforation is done in the lateral sinus mucosal wall, sinus bacteriological swab is taken to assess the baseline sinus flora present and small amount of the graft material is placed inside the sinus cavity and another part is placed under the sinus membrane overlying the palatine bone. Repositioning of the periosteal flap along with suturing in layers of the wound.

Figure 9: showing perforation of the sinus mucous membrane.

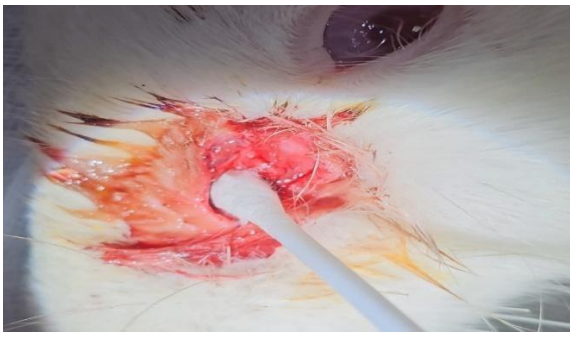

Figure 10: showing how the swab is taken from inside the sinus cavity.

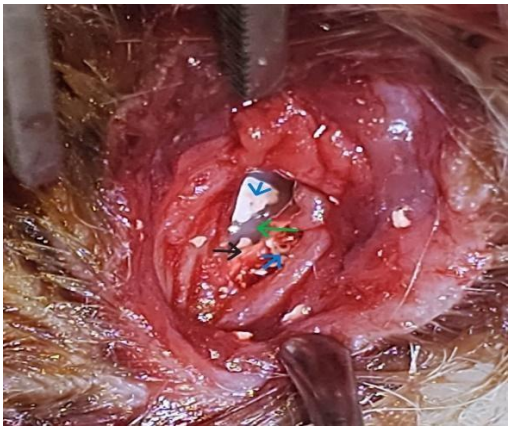

Figure 11: Showing the perforation in the sinus mucosa (green arrow), the sinus mucosa (black arrow), the bone graft material inside the sinus cavity and under the sinus mucous membrane (blue arrow).

In group III, the same steps done in group two were repeated but after two weeks of the operation, the wound was reexplored and removal of the graft material from inside the sinus cavity was done. Another bacteriological swab was taken to detect changes occurring in the sinus flora with this graft displacement and possible contamination from the sinus cavity. The wound was then closed in layers again.

Postoperative Care

All animals were kept under appropriate veterinary care and nutritional support. The animals received food and filtered water ad libitum. An animal monitoring protocol was carried out during the entire experimental period. The rabbits were carefully monitored during the healing period, and antibiotics (enrofloxacin; 5 mg/kg, Baytril, Bayer) were administered for the first 5 days after each intervention [6].

Figure 12: Showing warming the animal in the postoperative recovery period to avoid hypothermia

At the 4th week, Euthanasia was done using a lethal dose of IM Ketamine+ Xylazine and histopathological evaluation was performed.

Steps for histopathological Evaluation

We adopted the method used by M. E. Pereira et al., where all rabbits were euthanized, then decapitated, and all extraneous tissues, including the mandible, brain, eyes, skin, and muscle, were removed from the head [7].

Fixation

The head was partially immersed in 10% neutral-buffered formalin, and fixative was introduced into the nasal cavity by retrograde perfusion through the nasopharynx, using a syringe. The nasal cavity was then fully immersed in 10% neutral buffered formalin and fixed with the head for a minimum of seven days prior to sectioning [7].

Decalcification

The fixed maxilla was wrapped in gauze and immersed in a hydrochloric acid/water 25:1 decalcification solution for eight days. The decalcification solution was renewed at least four times during the process.

Sampling

Following decalcification, the maxilla was rinsed in running water overnight. Transverse sections (up to 5 mm) were made and processed in 28 _ 35 _ 6 mm cassettes with the cranial surface facing down [7].

Processing and Sectioning

Tissues were processed and embedded in paraffin wax using conventional methodology. Five-micron–thick sections were microtomed from the anterior face, mounted on 75x 25x 1 mm glass slides, stained with hematoxylin and eosin (H&E), and examined microscopically by an independent pathologist. Slides were scanned and images were processed using ImageJ scanner and viewer software [7].

Microbiological Evaluation

Opening and exposure of the anterior wall of the maxillary sinuses were performed unilaterally in group II and III rabbits, using swabs to collect secretion from them. The materials were kept at room temperature without exposure to sunlight and sent to the laboratory within 1 to 2 hours after collection. All samples were prepared on slides and stained by the Gram technique for bacteriological analysis, then the slides were stained with methyl violet, fixed with Lugol's solution, discolored with ethyl alcohol, and again stained with safranin. Slide reading was performed with light microscopy under oil immersion objective (100×). After the bacterioscopic analysis, the materials were seeded in blood agar, chocolate agar, and MacConkey agar. Plates of these agars were incubated at 35 ± 2◦C. Daily readings of the plates were performed up to 72 hours for MacConkey agar, blood agar and chocolate agar media [8].



Figure 13: Showing blood agar, chocolate agar, MacConkey agar and the culture swab.

Figure 14: Showing the swab streaked on a blood agar.

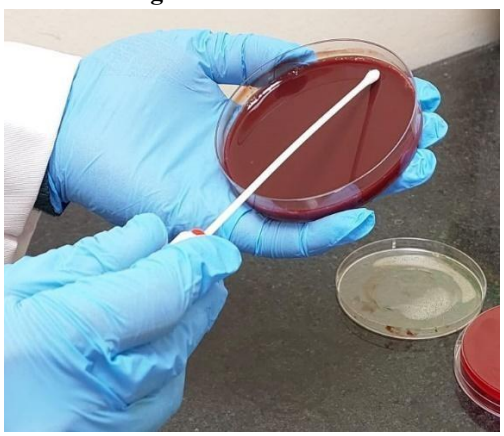

Figure 15: Showing the swab streaked on a chocolate agar.

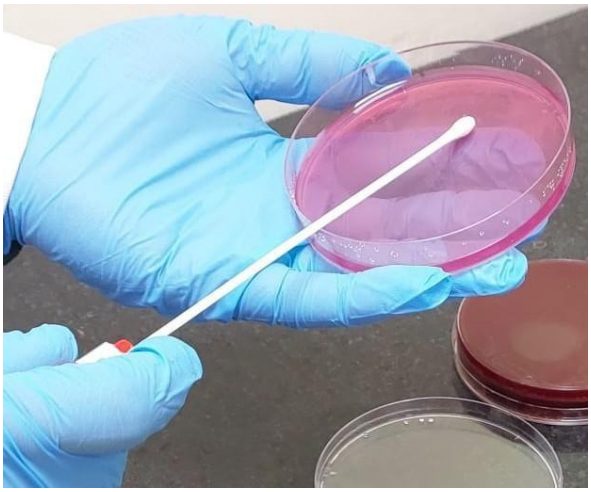

Figure 16: Showing the swab streaked on a MacConkey agar.

(B)

Figure 17: The incubators used in our study for anaerobic and aerobic cultures respectively

Data management

The statistical program Statistical Package for the Social Sciences (SPSS) 18.0 (SPSS Inc., Chicago, IL, USA) was used to analyze the data. Tables and graphs were used to display the descriptive information. The 95% threshold of statistical significance, or P value 0.05, was set.

Ethical consideration

The study was approved by the Research and Ethics committee in the Faculty of Medicine, Suez Canal University. (protocol No. 5044, 11 September 2022).

All experimental procedures were approved by institutional committee of animal care and use in the Faculty of Medicine Suez Canal University.

The animals hadn't been loaded by non - justified burden.

No Mutilation of the animals.

Animals were restrained and transported in a human manner.

Taking care of the animals during the peri-operative period with no negligence

Care for the animal's husbandry was taken in the animal house.

Care to avoid infectious diseases was taken.

Restrict the use of the same animal in more than one research.

Animals were sacrificed using a lethal dose of IM Ketamine+ Xylazine.

Disposal of the animal's body was done in a proper manner.

Results

Microbiological assessment

Table 1: Comparison of microbiological baseline evaluation.

	Group II N=14	Group III N=14	Total (N=28)	P-value
Negative n, %	7(50%)	9(64.3%)	16(57.1%)	0.707
Positive n, %	7(50%)	5(35.7%)	12(42.9%)	
Pasteurella multocida	4(28.6%)	3(21.4%)	7(25%)	
Staphylococcus aureus	2(14.3%)	2(14.3%)	4(14.3%)	
Streptococcus pneumonia	1(7.1%)	0(0%)	1(3.6%)	

Chi square test used. *Statistically significant as p<0.05.

Table (1) showed that there was statistically insignificant difference in bacterial growth among the studied groups (p=0.707) at baseline evaluation. Group II had higher growth (50%) than group III (35.7%) with insignificant

difference. In group II, 28.6% had Pasteurella multocida, 14.3% had staphylococcus aureus and 7.1% had streptococcus pneumonia. Among group III, 21.4% had Pasteurella multocida and 14.3% had staphylococcus aureus.

Table 2: Comparison of baseline sinus flora versus bacterial growth 2 weeks after migration of the graft in group III.

	Baseline N=14	After 2 weeks N=14	P-value
Negative n, %	9(64.3%)	5(35.7%)	**0.004***
Positive n, %	5(35.7%)	9(64.3%)	
Pasteurella multocida	3(21.4%)	4(28.6%)	
Staph aureus	2(14.3%)	1(7.1%)	
Strept. pneumonia	0(0%)	2(14.3%)	
E. coli	0(0%)	1(7.1%)	
Pseudomonas Aeruginosa	0(0%)	1(7.1%)	

Mc Nemar test used. *Statistically significant as p<0.05.

Table (2) showed that among group III, there was significant increase in bacterial growth from (35.7%) to (64.3%) after 2 weeks with statistically significant difference (p=0.004). After 2 weeks, microbiological evaluation detected 2 cases with streptococcus Pneumonia, one case with Escherichia coli, one case with pseudomonas aeruginosa and one case with Pasteurella multocida.

Histopathological evaluation

Histopathological study of sinonasal mucosa and the underlying submucosal soft tissue and bone sections.

The evaluated structures included the integrity of the mucosa, the inflammatory infiltrate surrounding the graft and the percentages of new mineralized bone after sinus lifting procedure.

Group I

At 4 weeks, central areas of the new compartment under the elevated sinus membrane were filled with minimal inflammatory infiltrate of lymphocytes and macrophages. Active new bone formation was observed under the elevated sinus membrane, with many osteoblasts and osteocytes were observed. There were no thinning nor perforation of the Schneiderian membrane. Submucosal mucous glands were preserved. There was no connective tissue fibrosis, (Figures 18).

Group I

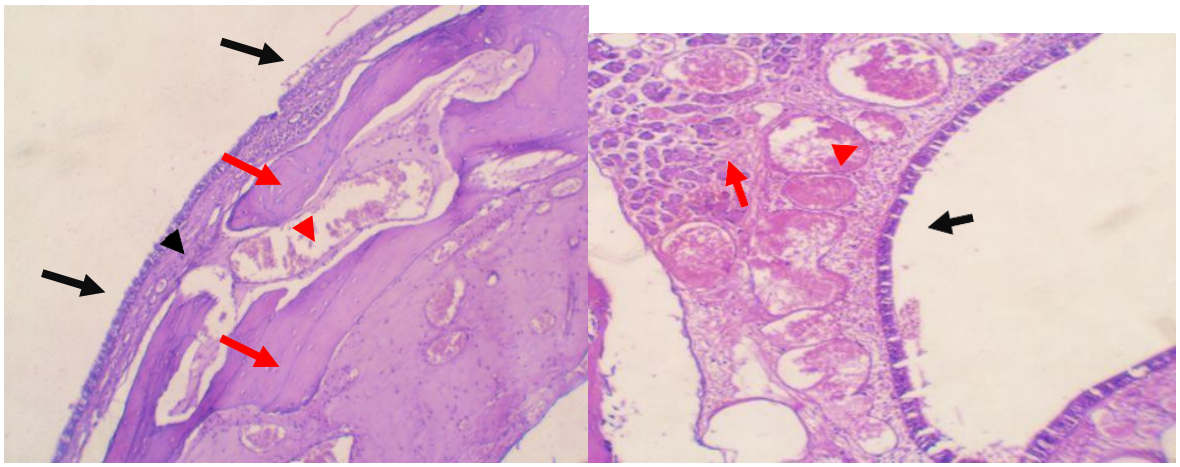

(B)

Figure 18:

The operated side:

The nasal mucosa integrity is preserved (Black arrows). The grafted material is seen under the mucosa (Red arrow) surrounding cartilage (Red arrowhead). There is mild associated lymphoid infiltrate (Black arrowheads) (H&E, 10x)

B) The control side:

Nasal mucosa is intact (Black arrow). There is underlying dilated congested blood vessels (Red arrows) and mucous glands (Red arrowhead) (H&E, 10x).

Group II

At 4 weeks, central areas of the new compartment under the elevated sinus membrane were filled with dense inflammatory infiltrate of lymphocytes and macrophages (Figure 19). No new bone formation was observed under the elevated sinus with many Chondroblasts were observed there. There were thinning and perforation of the Schneiderian membrane with no attempts of healing for perforation. There was some connective tissue fibrosis, (Figures 19).

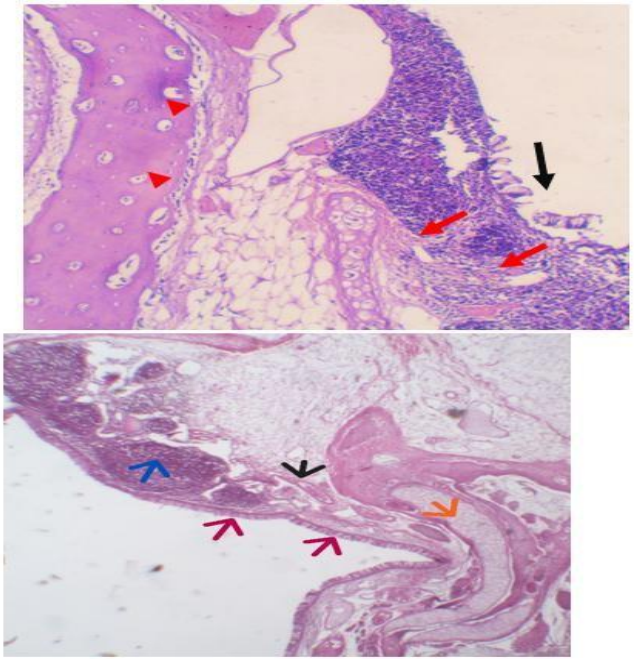

Figure 19: (A) (B)

The operated side: The site of perforation is marked by dense chronic inflammation (Black arrow), fibrosis (Red arrow) and the grafted bony material (Arrowheads) (H&E, 10x).

The control side: Nasal mucosa is intact (Red arrow). There is underlying lymphoid follicles (Blue arrow), congested blood vessels (Black arrow) and uniform cartilage (Orange arrow) (H&E, 10x)

Group III

At 4 weeks, central areas of the new compartment under the elevated sinus mucosa were filled with dense chronic inflammation of lymphocytes and macrophages (Figure 20). Mild new bone formation was observed under the elevated sinus with many osteoblasts and osteocytes. There were mild thinning and perforation of the Schneiderian membrane with attempts of healing for perforation present as a thin epithelized lining on the mucosal surface with small foci of erosion. Submucosal mucous glands were preserved but decreased in number. There was no connective tissue fibrosis. (Figures 20).

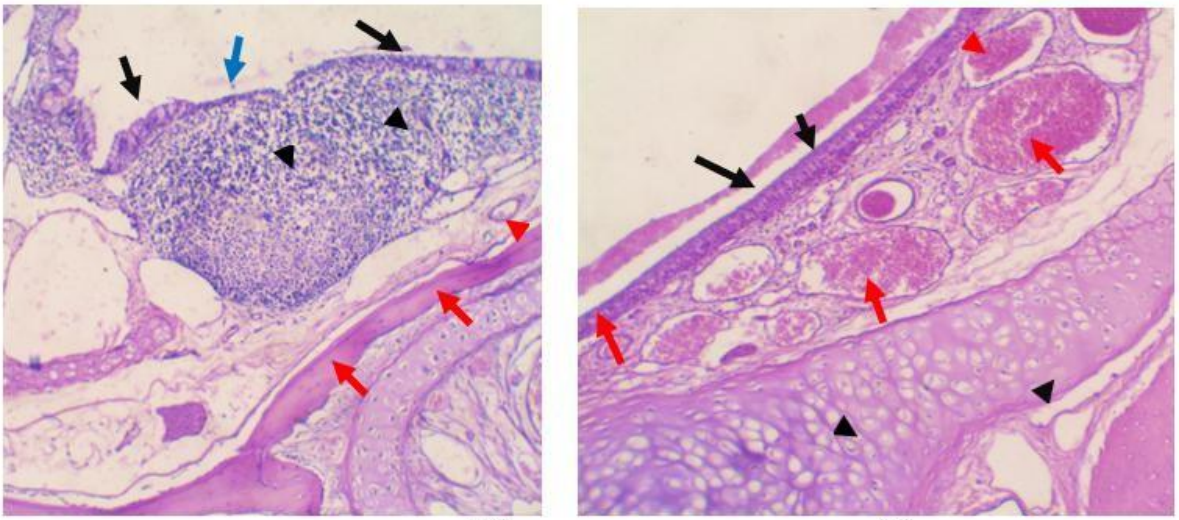

(A) (B)

Figure 20:

The operated side: The sinus mucosa integrity is almost preserved (Black arrows) with focal ulceration (Blue arrow). There is lymphoid infiltrate under the mucosa (Black arrowheads). The grafted material is seen under the mucosa (Red arrow). There are dilated blood vessels (Red arrowheads) (H&E, 10x)

The control side: The sinus mucosa is intact (Black arrow). There are no underlying lymphoid follicles. There is underlying congested blood vessels (Red arrows) and uniform cartilage (Black arrowhead) (H&E, 10x)

Table 3: Comparison of inflammatory process, fibrosis, histological changes of the underlying sinus bony wall among the study groups.

	Group I N=14	Group II N=14	Group III N=14	P-value
Inflammatory infiltrate (%)	10%	75%	45%	**0.002***
New bone formation (%)	90%	0%	35%	**<0.001***
Thinning and Perforation of the Schneiderian membrane (%)	0%	85%	20%	**<0.001***
Fibrosis (%)	0%	10%	0%	**0.317**

In table (3), inflammatory cells, new bone formation, thinning and perforation of the Schneiderian membrane showed statistically significant differences between groups as $p<0.05$. Group II had the highest inflammatory infiltrate (75%) and thinning and perforation of the Schneiderian membrane (45%) than other groups with statistically significant differences ($p=0.002$ and <0.001, respectively), while regarding new bone formation only group II had no new bone formation compared with group I (90%) and group III (35%) with statistically significant difference ($p<0.001$). Connective tissue fibrosis is also evident in group II.

Discussion

According to our knowledge, no prior research has examined the variable changes that may occur in the sinus cavity, the sinus mucous membrane, and the submucosal tissues in cases of successful intact sinus mucosal membrane elevation with graft placement, in cases of sinus lifting up on a perforated sinus membrane, and in addition to the bacteriological changes that occur in cases with perforated sinus membrane. Few studies have concentrated on the changes that occur in the sinus mucosa following sinus augmentation [9]. Therefore, the purpose of this research was to evaluate the bacteriological and histological effects of a sinus lifting technique on the maxillary sinus using a rabbit model.

For this animal experiment, forty-two rabbits were used. In order to ensure that there were no active infections present at the time of the procedure and to evaluate the sinus bacterial flora, the rabbits were split into three groups: Group I (n=14) had the operation performed on top of an intact sinus mucosa, placing the bone graft material beneath an intact sinus mucosal membrane. Group II (n=14) had the operation performed on top of an intentionally perforated sinus mucosa, placing the bone graft material inside the sinus cavity and beneath the sinus membrane. Group III (n=14) underwent the same procedure as group II, but after two weeks, the graft material was removed using a different swab that was taken for bacteriological culture. This was done to determine the histopathological effect of removing grafts that were inadvertently displaced into the sinus cavity, which can happen during surgery or later, particularly upon a perforated Schneiderian membrane, and to detect changes in the sinus bacterial flora following the graft's placement inside the sinus cavity.

In the baseline assessment of sinus flora, 3.6% had streptococcus pneumonia, 14.3% had staphylococcus aureus, and 25% had Pasteurella multocida. The bacterial growth of the groups under study was statistically insignificantly different (p=0.707), with group II showing a greater growth rate (50%) than group III (35.7%). Staphylococcus aureus was present in 14.3% of group II, streptococcus pneumonia was present in 7.1%, and Pasteurella multocida was present in 28.6%. Staphylococcus aureus was present in 14.3% of group III, whereas Pasteurella multocida was present in 21.4%. In the two groups with purposefully perforated sinus membranes, these results were at baseline evaluation at the beginning of the experiment. However, upon purposeful sinus membrane perforation and examination of the rabbits' sinus cavities, no obvious sinus discharge or indications of inflammation were found, which may indicate that these could be typical bacterial flora of the upper respiratory system.

This is consistent with multiple studies showing that the most prevalent commensal bacteria in rabbits are Pasteurella multocida, while staphylococcus aureus and streptococcus pneumonia are commensal bacteria of the rabbits' upper airway. These bacteria can become pathogenic unless the host's immunity is compromised [10–12].

In contrast, group III saw a statistically significant increase in bacterial growth after two weeks, with a proportion of positive cultures (64.3%) compared to the baseline examination at week 0 (35.7%) (p=0.004). Two new instances of Streptococcus pneumonia, one case of Escherichia coli, one case of Pseudomonas aeruginosa, and a new growth of Pasteurella multocida were discovered during microbiological assessment. These microbiological changes after just two weeks from a baseline evaluation of a negative culture indicate that there is an active infection linked to the graft displacement inside the sinus cavity. The group with sinus membrane perforation and graft displacement inside the sinus cavity showed a statistically significant difference between baseline and two-week evaluations.

The reported incidence of rhinosinusitis following sinus lifting is low, ranging from 2% to 4% and 4.2% to 8.4%, respectively, according clinical studies on humans [4,13].

We examined this frequent issue with maxillary sinus augmentation in the current research as a precursor to graft failure and subsequent maxillary sinus problems. Regarding the Schneiderian membrane's thinning and perforation, we discovered on histological analysis that group I's sinus membrane was intact and that none of these conditions existed. Twenty percent of patients in group III, where the displaced graft inside the sinus was removed, had thinning and perforation of the Schneiderian membrane, indicating the significance of removing the displaced grafts from the sinus cavity in healing of Schneiderian membrane perforations. In group II, where the graft was displaced inside the sinus cavity, 85% of the cases had residual sinus membrane perforation at week four. This difference was statistically significant ($p<0.001$).

The histopathologic findings of maxillary sinusitis associated with foreign bodies were not well documented. The majority of them are iatrogenic, mostly as a result of dental and oral treatments, and are caused by aberrant connections between the sinus and mouth cavities. In order to distinguish between odontogenic sinusitis and rhinosinusitis that is not caused by a foreign body or odontogenic etiology, a research documented three instances

of chronic maxillary sinusitis brought on by distinct foreign bodies of oral and dental origin. In contrast to odontogenic sinusitis, which exhibits distinct patterns of foreign body-related inflammatory response and stromal fibrosis, rhinosinusitis caused by other etiologies is often linked to eosinophils, allergic mucin, edema, and fungal infection [14].

According to our findings, the majority of inflammatory cells found, particularly in groups II and III, were lymphocytes, multinucleated giant cells, and macrophages, indicating histopathological changes related to foreign bodies. A small number of cases in group II displayed acute inflammatory cells, such as neutrophils, which reflected the acute inflammatory changes that occurred after graft displacement inside the sinus cavity. Furthermore, the rabbits in group II exhibited the greatest prevalence of inflammatory infiltration, with 75% of them exhibiting it. Connective tissue fibrosis is also seen in group II, and these results are greater there than in the other groups with statistically significant differences ($p=0.002$, <0.001, and <0.001, respectively). The sort of inflammatory cells that are present within the sinus cavity after implant displacement has not been the subject of any prior experimental research.

The integrity of the sinus Schneiderian membrane has a significant impact on how well bone grafting enhances the formation of new bone. In as many as 90% of our cases, we found that group I, which had an intact sinus membrane, showed positive evidence of new bone formation; however, group II, which had a perforated sinus membrane, did not exhibit any new bone formation attempts. The significance of an intact Schneiderian membrane in the formation of new bone following sinus augmentation is demonstrated by the fact that 35% of rabbits in Group III, which had the displaced graft removed from the sinus cavity after two weeks, had positive evidence of new bone formation at the 4-week evaluation with a statistically significant difference ($p<0.001$).

The area of the newly produced bone in the perforation group was substantially less than that in the intact group (18.7% and 25.5%, respectively, $p =.028$), which is consistent with another experimental investigation on rabbits by Paik et al. Schneiderian membrane perforation has a negative impact on the formation of new bone, especially in the vicinity of the membrane perforation, as evidenced by the significantly lower amount of newly formed bone in the area near the perforated Schneiderian membrane compared to the intact group (18.7% and 26.1%, respectively, $p <.05$) [6].

In a thorough review, Craig et al. emphasized the value of working in tandem with otolaryngologists. They found that preoperative evaluations, such as patient history, computed tomography (CT) or cone-beam CT (CBCT) scans, and nasal endoscopy, are crucial for reducing the risks associated with sinonasal health and for proactively diagnosing and treating sinonasal conditions, particularly those that affect mucociliary clearance and sinus drainage. In addition to managing postoperative problems such as maxillary sinusitis of odontogenic origin after Schneiderian membrane rupture or implant displacement within the sinus cavity, these major risk factors need otolaryngological intervention prior to sinus augmentation [15].

Allevi et al. did a comprehensive evaluation of 581 research to determine the best ways to manage sinusitis after dental implantation. Eight studies (181 patients) were chosen from among all the investigations. Every study used endoscopic sinus surgery, often in conjunction with intraoral accesses, and evaluated treatment success endoscopically, with a 94.7% success rate. Seven out of 15 failures were managed with further antibiotic treatments, and seven more patients required surgical revision. This highlights the significance of endoscopic sinus surgery, which has high success rates and is the most common therapy of choice for sinusitis after tooth implantation [16].

Our study's limitation is that it does not provide a histomorphometric evaluation of the volume of bone gain in the three different groups to support the importance of maintaining an intact Schneiderian membrane. The perforated group is expected to gain the least volume of bone, with the graft escaping inside the sinus cavity. Nevertheless, we had discussed the various histopathological and bacteriological changes that may occur in the maxillary sinus following this surgical procedure, which is becoming more and more popular these days. Another drawback of our research is its length; a longer follow-up period could allow for a more thorough examination of the impact of sinus lifting on the maxillary sinus and its surrounding tissues.

Conclusion

If the maxillary sinus lifting is performed on top of an undamaged Schneiderian membrane, it is a rather safe and effective treatment. Although a little inflammatory response is anticipated, our data clearly shows new bone growth. The graft material is exposed by Schneiderian membrane penetration within the sinus cavity, which may impede the deposition of new bone for the intended implant installation and cause inflammatory cell aggregation.

In order to improve patient outcomes by increasing the predictability and safety of maxillary sinus lifting operations, this research also emphasizes the need of multidisciplinary cooperation between the otolaryngologist and oral surgeon...

REFERENCES

1. Esposito M, Felice P, Worthington H V. Interventions for replacing missing teeth: augmentation procedures of the maxillary sinus. Cochrane database Syst Rev [Internet]. 2014 May 13;2014(5):CD008397–CD008397.

2. Akcay H, Ulu M, Kelebek S, Aladag I. Benign Paroxysmal Positional Vertigo Following Sinus Floor Elevation in Patient with Antecedents of Vertigo. J Maxillofac Oral Surg [Internet]. 2016/04/02. 2016 Jul;15(Suppl 2):351–4.

3. Hernández-Alfaro F, Torradeflot MM, Marti C. Prevalence and management of Schneiderian membrane perforations during sinus-lift procedures. Clin Oral Implants Res [Internet]. 2007;19(1):91–8.

4. Aung K, Htay T. In BPPV, canalith repositioning maneuver increased symptom resolution vs. vestibular suppressants. Ann Intern Med [Internet]. 2023;176(4):JC47.

5. Jacob RGM, Ervolino da Silva AC, Chaushu L, Lang NP, Borges Duailibe de Deus C, Botticelli D, et al. Evaluation of Two Configurations of Hydroxyapatite and Beta-Tricalcium Phosphate in Sinus Grafts with Simultaneous Implant Installation: An Experimental Study in Rabbits. Dent J. 2023;11(5):121.

6. Pikos MA. Maxillary Sinus Membrane Repair: Update on Technique for Large and Complete Perforations. Implant Dent [Internet]. 2008;17(1):24–31.

7. Pereira ME, Macri NP, Creasy DM. Evaluation of the Rabbit Nasal Cavity in Inhalation Studies and a Comparison with Other Common Laboratory Species and Man. Toxicol Pathol [Internet]. 2011;39(5):893–900.

8. Dolci ELL, Campos CAC de, Silva L da, Dolci RLL, Dolci JEL. Avaliação da capacidade de um modelo experimental para indução de rinossinusite bacteriana em coelhos. Braz J Otorhinolaryngol. 2014;80:480–9.

9. Sala YM, Lu H, Chrcanovic BR. Clinical outcomes of maxillary sinus floor perforation by dental implants and sinus membrane perforation during sinus augmentation: a systematic review and meta-analysis. J Clin Med. 2024;13(5):1253.

10. Kalyvas D, Kapsalas A, Paikou S, Tsiklakis K. Thickness of the Schneiderian membrane and its correlation with anatomical structures and demographic parameters using CBCT tomography: a retrospective study. Int J Implant Dent [Internet]. 2018 Oct 19;4(1):32.

11. Lovasova K, Kachlik D, Rozpravkova M, Matusevska M, Ferkova J, Kluchova D. Three-dimensional CAD/CAM imaging of the maxillary sinus in ageing process. Ann Anat - Anat Anzeiger [Internet]. 2018;218:69–82.

12. Ozcan KM, Hizli O, Ulusoy H, Coskun ZU, Yildirim G. Localization of orbit in patients with maxillary sinus hypoplasia: a radiological study. Surg Radiol Anat [Internet]. 2018;40(10):1099–104.

13. Molina A, Sanz-Sánchez I, Sanz-Martín I, Ortiz-Vigón A, Sanz M. Complications in sinus lifting procedures: Classification and management. Periodontol 2000 [Internet]. 2022;88(1):103–15.

14. AbdullGaffar B, Manzlgi M, Awadhi F. Foreign bodies in sinonasal tissues: A potential pitfall yet a hint to oroantral fistulas. Int J Surg Pathol. 2023;31(3):294–300.

15. Craig JR, Saibene AM, Felisati EG, Felisati G. Collaboration between otolaryngologists and oral surgeons in maxillary sinus elevation planning. Clin Implant Dent Relat Res. 2024;26(6):1181–9.

16. Allevi F, Fadda GL, Rosso C, Martino F, Pipolo C, Cavallo G, et al. Treatment of sinusitis following dental implantation: a systematic review and meta-analysis. Am J Rhinol Allergy. 2022;36(4):539–49.

.